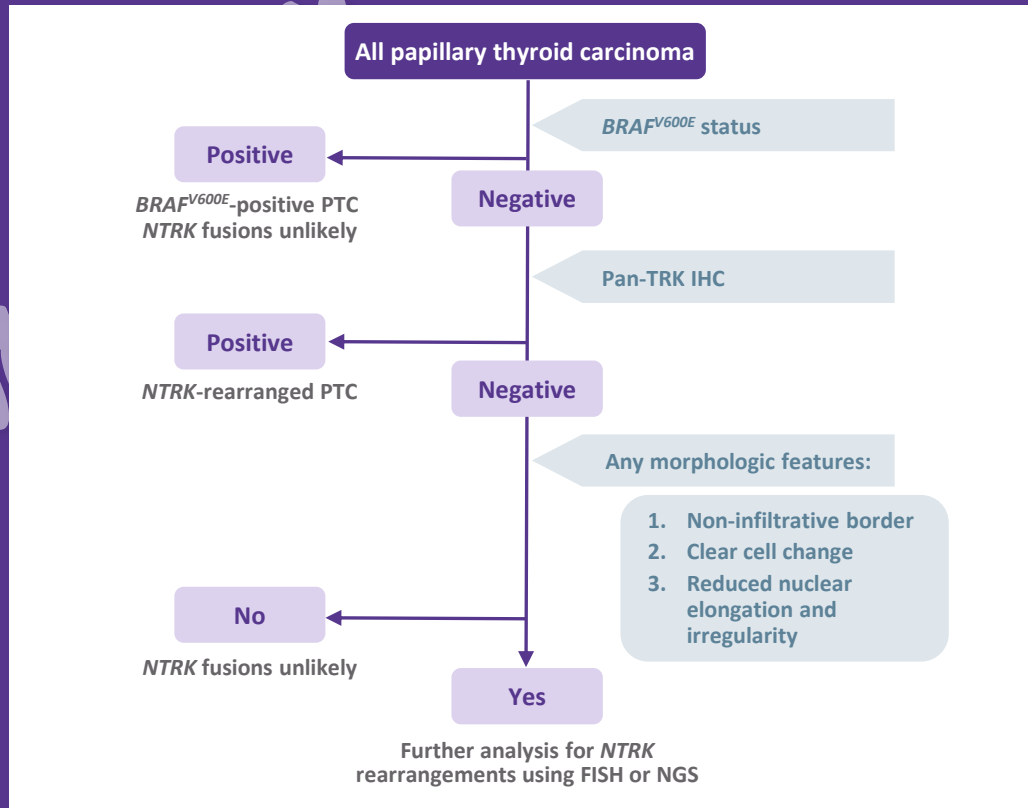
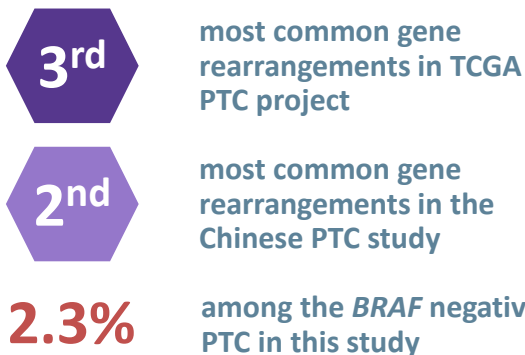


## Thyroid Carcinoma



## *NTRK1/3* fusions in PTC



## CONCLUSIONS

- 3 morphologic features for the diagnosis of *NTRK1/3*-rearrangement PTC identified:
  - Non-infiltrative tumour border, clear cell change and reduced nuclear elongation and irregularity
- Pan-TRK IHC interpretation with caution for PTC : lower sensitivity for *ETV6-NTRK3* rearranged PTC

FISH, fluorescence in situ hybridization; IHC, immunohistochemistry; NGS, next-generation sequencing; NTRK, neurotrophic tyrosine receptor kinase; PTC; papillary thyroid carcinoma; TCGA, The Cancer Genome Atlas; TRK, tropomyosin receptor kinase.